



## Seven-second X-ray scan accurately detects severity of heart valve regurgitation in patients with repaired congenital heart defects

Dynamic chest radiography bridges the gap between echocardiography and cardiac MRI—expanding diagnostic options when cardiac MRI is unavailable or contraindicated

**Fukuoka, Japan**—Researchers at Kyushu University have developed a simple, rapid, and low-radiation X-ray technique that can evaluate the severity of a heart condition known as pulmonary valve regurgitation—a common and clinically significant complication after surgical repair of a congenital heart defect known as Tetralogy of Fallot. The test only requires a scan of seven seconds and can evaluate the patient with 93% accuracy.

The new technique, published in the journal *Radiology*, can help diagnose patients who cannot undergo traditional diagnostic methods, improve access to accurate diagnosis, greatly improve efficiency, and bridge the gap between echocardiography and cardiac MRI.

Tetralogy of Fallot, or TOF, is the most common cyanotic congenital heart defect that affects approximately 1 in 3,500 newborns. It is characterized by defects in the heart's structure that reduce blood flow to the lungs, resulting in low oxygen levels.

"Thankfully, with advances in surgical techniques and patient care, today over 90% of patients survive into adulthood," explains Assistant Professor [Yuzo Yamasaki](#) of [Kyushu University Hospital Radiology Center](#) and first author of the study. "However, Pulmonary Regurgitation (PR) is a common long-term complication after surgical repair that can lead to increased risk of sudden cardiac arrest if left untreated. Monitoring PR severity is essential to determine when patients should be treated."

Cardiac MRIs are the standard practice for quantifying the severity of PR. However, the procedure can be limiting to patients since MRIs can be expensive and require expertise and equipment typically available at specialized facilities. Additionally, MRIs cannot be performed in patients with incompatible pacemakers or defibrillators or in those with claustrophobia.

To overcome these obstacles, the research team focused on utilizing an emerging imaging technique called dynamic chest radiography, or DCR. This method uses conventional X-ray equipment to capture sequential chest images while the patient holds their breath.

"DCR images are usually assessed visually. However, for this study, we analyzed temporal changes in pixel values over the pulmonary arteries in captured sequential images. These changes were converted into waveforms, allowing us to quantify blood flow dynamics," continues Yamasaki. "In patients with PR, blood flows back into the right ventricle during each heartbeat. The more severe the regurgitation, the more blood flows and that shows up as a more prominent waveform. We tested this new technique in 58 post-surgical patients and 14 healthy volunteers. We were able to detect severe PR with an accuracy of 93%."

Moreover, because DCR uses X-ray, it requires no contrast media and uses minimal radiation, approximately 0.2 mSv. A standard chest CT is around 6 mSv.

The team hopes that the implementation of their new technique will help both patients with PR access to quality care and hospitals reduce costs.

"DCR can also be used to study and diagnose other heart diseases like heart failure and pulmonary hypertension," concludes Yamasaki. "We are currently planning a multicenter study to further validate these findings and hopefully establish DCR in routine clinical practices."

###

For more information about this research, see "Novel Dynamic Chest Radiography Technique for Assessing Pulmonary Regurgitation in Repaired Tetralogy of Fallot," Yuzo Yamasaki, Koji Sagiya, Tomoyuki Hida, Takuya Hino, Megumi Ikeda, Kosuke Tabata, Daisuke Toyomura, Kenichiro Yamamura, Ichiro Sakamoto, Masateru Kawakubo, Ryoichi Watanabe, Hidetake Yabuuchi, Hyemoun Chung, Jongmin Lee, Kousei Ishigami. *Radiology* <https://doi.org/10.1148/radiol.252344>

### About Kyushu University

Founded in 1911, [Kyushu University](#) is one of Japan's leading research-oriented institutions of higher education, consistently ranking as one of the top ten Japanese universities in the Times Higher Education World University Rankings and the QS World Rankings. Located in Fukuoka, on the island of Kyushu—the most southwestern of Japan's four main islands—Kyushu U sits in a coastal metropolis frequently ranked among the world's most livable cities and historically known as Japan's gateway to Asia. Its multiple campuses are home to around 19,000 students and 8,000 faculty and staff. Through its [VISION 2030](#), Kyushu U will "drive social change with integrative knowledge." By fusing the spectrum of knowledge, from the humanities and arts to engineering and medical sciences, Kyushu U will strengthen its research in the key areas of decarbonization, medicine and health, and environment and food, to tackle society's most pressing issues.

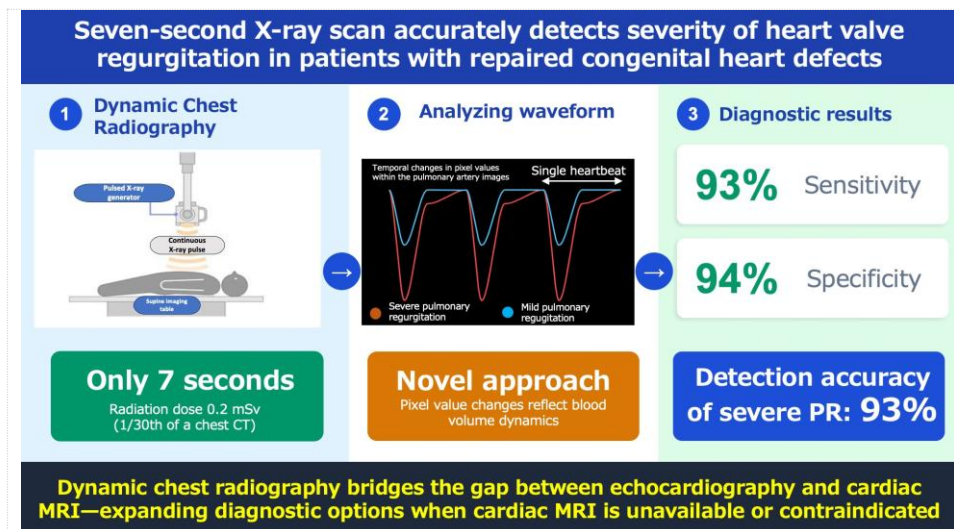


Fig. 1. Graphical abstract of the research.

Kyushu University researchers use Dynamic Chest Radiography (DCR) to evaluate the severity of Pulmonary Regurgitation (PR), a common complication after treatment of the congenital heart disease Tetralogy of Fallot. The analysis only requires the patient to hold their breath for seven seconds for a sequence of images of their heart to be taken. The images are then analyzed and extracted into a waveform that can show the severity of PR. The new technique's detection accuracy of severe PR is 93%, with a sensitivity of 93% and a specificity of 94%. (Yuzo Yamasaki/Kyushu University)

---

[Contact]

Yuzo Yamasaki, Assistant Professor

Kyushu University Hospital Radiology Center

Tel: +81 92-642-5695

E-mail: [yamasaki.yuzo.776@m.kyushu-u.ac.jp](mailto:yamasaki.yuzo.776@m.kyushu-u.ac.jp)